

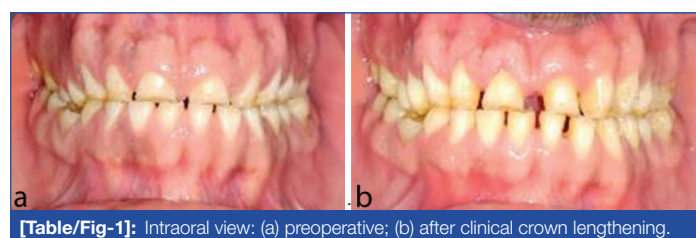
Full Mouth Rehabilitation of a Patient with Amelogenesis Imperfecta using Twin Stage Procedure

VINEET SHARMA¹, JYOTI PALIWAL², KAMAL KUMAR MEENA³, ASHISH DADARWAL⁴, AMIT SINGLA⁵

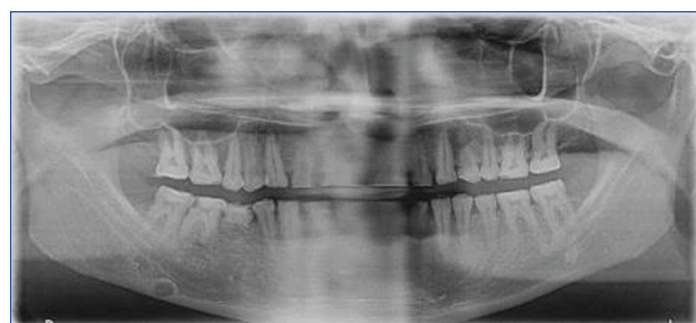
(CC) BY-NC-ND

Keywords: Disclusion, Hobo and takayama, Occlusal rehabilitation

A 26-year-old male patient came to the Department of Prosthodontics with the chief complaint of compromised appearance for 10-12 years with generalised sensitivity to hot and cold and difficulty in chewing for two years. There was no significant medical history. Extraoral examination revealed no facial asymmetry and muscle tenderness. The mandibular movements were also within normal limits. On intraoral examination, enamel was thin and all the teeth were smaller than normal. There was generalised spacing between anterior teeth, generalised attrition, yellow to brownish discoloration and dental caries in 47 and 85 [Table/Fig-1,2]. Radiographic examination revealed thin radiopaque layer of enamel with normal radiodensity [Table/Fig-2]. The younger sister of the patient also exhibited similar characteristics that indicate a family history.



[Table/Fig-1]: Intraoral view: (a) preoperative; (b) after clinical crown lengthening.

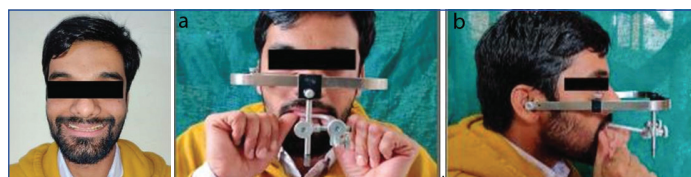

[Table/Fig-2]: Orthopantomogram (OPG) radiograph.

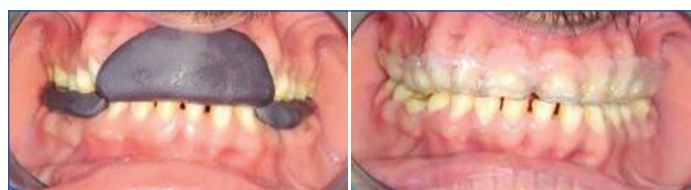Based on family history and clinical and radiographic findings, the patient was diagnosed as a case of Amelogenesis Imperfecta (AI) hypoplastic type [1]. A free-way space of 6 mm was evaluated. Based on all the clinical findings and freeway space evaluation, it was decided to reconstruct the dentition at 3 mm raised vertical dimension of occlusion. The possible treatment options were full mouth restorations using Hobo Twin Stage Technique or Pankey-Mann Schuyler Technique [2]. Finally, it was chosen to rehabilitate the patient with full mouth Porcelain Fused Metal (PFM) crown restorations using Hobo twin stage procedure due to single-step tooth preparation, pre-set values, no condylar and lateral records, and multiple visits [3].

After clinical crown lengthening [Table/Fig-1], diagnostic impressions were made in the irreversible hydrocolloid impression material (Zelgan 2002 Alginate; Dentsply) to obtain diagnostic casts. The portrait view and photographs were recorded [Table/Fig-3], face bow record was made and transferred to the semi-adjustable articulator (Hanau™ Wide-Vue, Whip Mix) [Table/Fig-4]. A Centric record was obtained

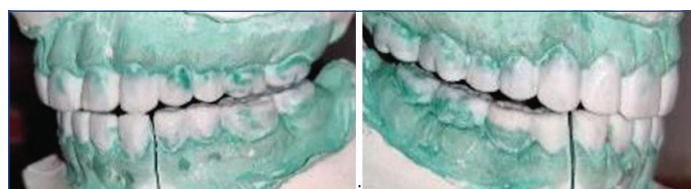
[Table/Fig-5] and mandibular cast along with centric record was mounted to the articulator. An occlusal splint (NMD Splint Plus; NMD Nexus Medodent) was fabricated at the 3 mm raised vertical dimension and the patient was kept in an observation period of six weeks to evaluate the adaptation to the altered Vertical Dimension of Occlusion (VDO) [Table/Fig-6]. A diagnostic wax-up was done thereafter and the putty index (Photosil; DPI) was made [Table/Fig-7,8]. All teeth were prepared in a single appointment with minimal occlusal reduction [Table/Fig-9]. Full arch impressions of prepared teeth were made using addition silicon elastomeric impression material (Photosil; DPI) [Table/Fig-10]. Chairside provisional crowns were fabricated using the putty index of the diagnostic wax-up. A maximum intercuspation in centric relation, as well as posterior disclusion in protrusive guidance, was established [Table/Fig-11-13].



[Table/Fig-3]: Preoperative portrait view. **[Table/Fig-4]:** Face bow record: (a) front view; (b) lateral view. (Images from left to right)



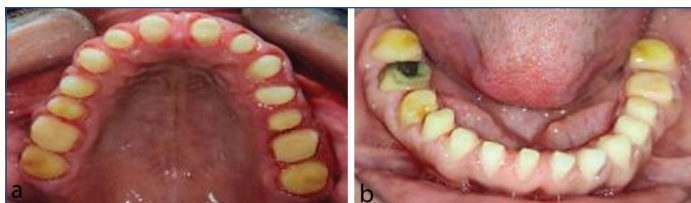
[Table/Fig-5]: Centric record; **[Table/Fig-6]:** Occlusal splint at 3 mm raised vertical dimension. (Images from left to right)



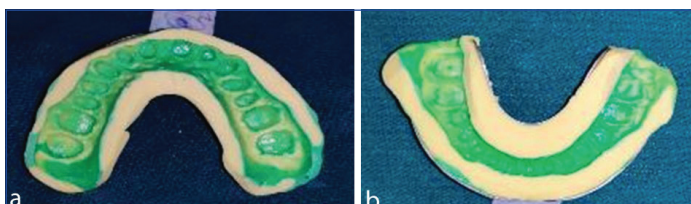[Table/Fig-7]: Diagnostic wax up.



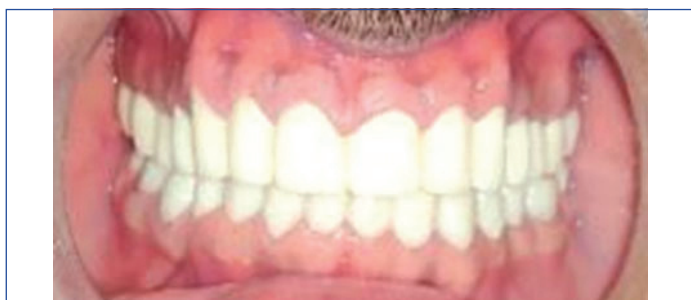[Table/Fig-8]: Putty Index of Diagnostic Waxed-up Cast.



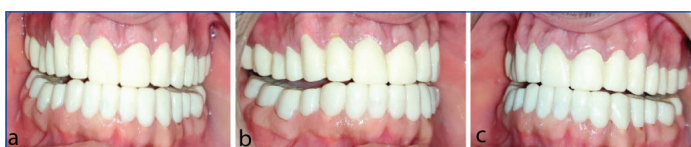[Table/Fig-9]: Full-arch teeth preparations: (a) maxillary arch; (b) mandibular arch.



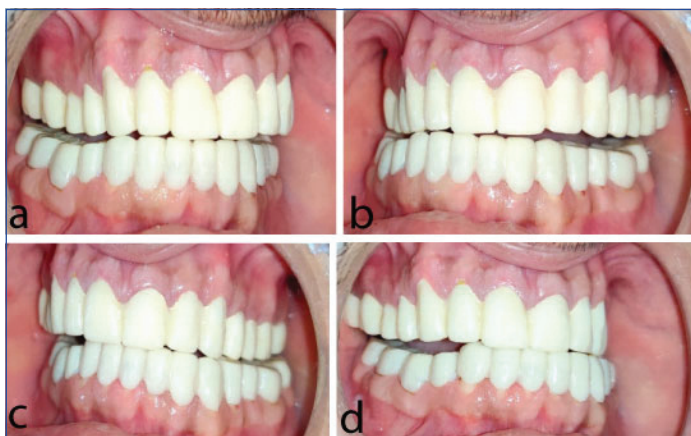[Table/Fig-10]: Master impression with addition silicon using two-step putty wash technique: (a) maxillary arch; (b) mandibular arch.



[Table/Fig-11]: Provisional crowns in centric relation.

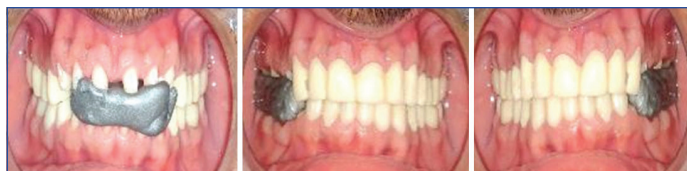

[Table/Fig-12]: Provisional crowns with disocclusion in protrusion: (a) Front view; (b) Right view; (c) Left view.



[Table/Fig-13]: Provisional crowns with disocclusion in eccentric movement: Right Working: (a) right view; (b) left view, Left Working: (c) left view; (d) right view.

The working casts were mounted on semi-adjustable articulator using facebow. To transfer the VDO and centric relation, provisional crowns were removed from left posterior regions, while the provisional crowns from right and anterior regions served as a stop. An interocclusal record material (Aluwax; Aluwax Dental Products Co.) was placed between the left maxillary and mandibular prepared teeth. Similarly, the provisional crowns were removed from right maxillary and mandibular region while they were seated in left and anterior regions. Interocclusal record was placed between the right maxillary and mandibular prepared teeth. A similar procedure was carried out in the anterior region as well. Using these three segmental interocclusal records, the mandibular cast was mounted [Table/Fig-14,15]. The provisional crowns were then luted with non eugenol temporary cement (NETC; Meta Biomed).

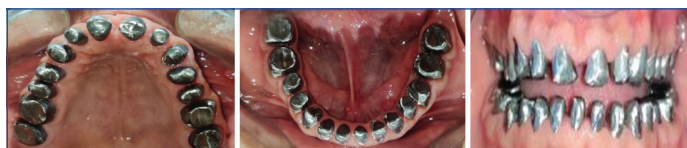


[Table/Fig-14]: Three segmental inter-occlusal records to transfer vertical dimension and centric relation.

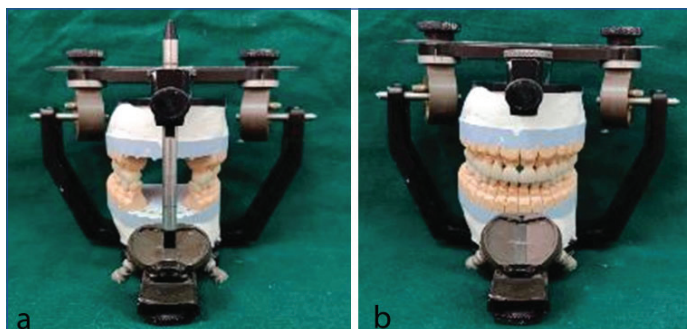


[Table/Fig-15]: Segmental inter-occlusal records transferred to articulator.

The wax patterns were fabricated and casted, and metal copings were tried in [Table/Fig-16]. In Stage 1, the anterior segment was removed from the cast, condylar and incisal guidance on the articulator were set to Hobo's condition 1 for providing an effective cuspal angulation of 25° [3]. Condition 1 settings for articulator included Sagittal condylar guidance at 25°, Bennett angle at 15°, Sagittal incisal guidance at 25° and Lateral incisal guidance at 10°. All teeth excluding anterior were built-up in porcelain and balanced in protrusive as well as lateral excursions. In Stage 2, the anterior segment of the cast was reassembled and condylar guidance and incisal guidance were set again (Condition 2) [Table/Fig-17]. Condition 2 settings for articulator included Sagittal condylar guidance at 40°, Bennett angle at 15°, Sagittal incisal guidance at 45° and Lateral incisal guidance at 20°.

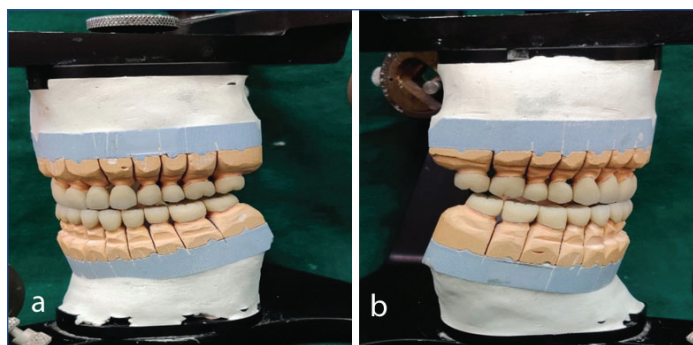


[Table/Fig-16]: Metal copings try in.




[Table/Fig-17]: (a) Condition 1 (b) Condition 2.

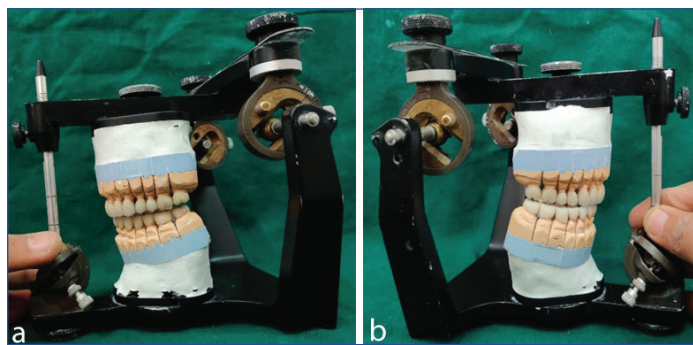
The anterior porcelain build-up was completed and anterior guidance was provided to generate a standard amount of disclusion in posterior teeth [Table/Fig-18-20]. The average values for posterior disclusion are 1.1 mm, 0.5 mm and 1.0 mm on protrusive movement, working side, and non working side during lateral movement respectively [3]. PFM crowns were cemented with polycarboxylate cement [Table/Fig-21-26]. Oral hygiene instructions were given and follow-up was carried out at an interval of six weeks. The follow-up examination of the patient revealed a healthy and comfortable stomatognathic system. A clear change was noticed by comparative evaluation of preoperative, provisional restoration and final restoration profile photographs of the



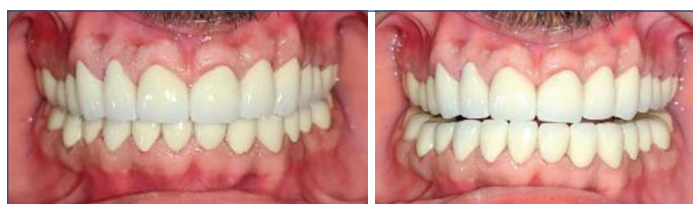[Table/Fig-18]: Condition 2; disocclusion in protrusion (a) Left view (b) Right view.



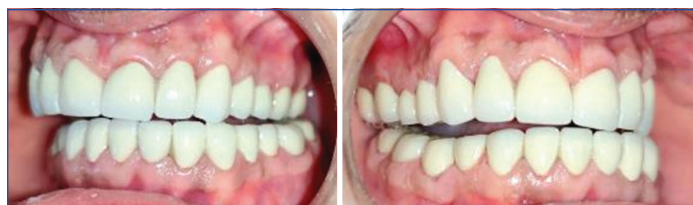[Table/Fig-19]: Condition 2; Disocclusion in left working eccentric movement: (a) left view; (b) Right view.



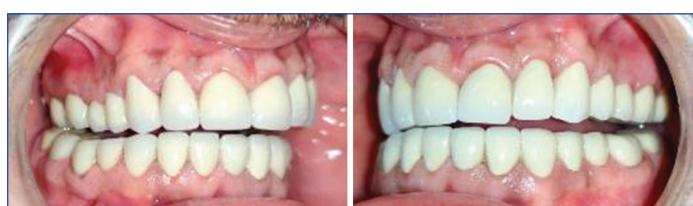[Table/Fig-20]: Condition 2; Disocclusion in right working eccentric movement: (a) Left view; (b) Right view.



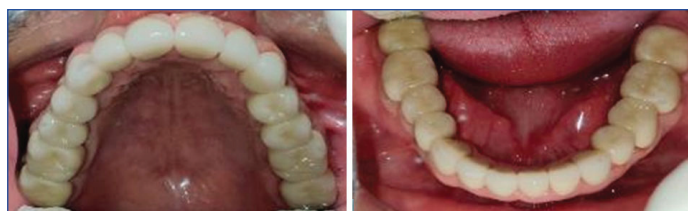[Table/Fig-21]: Cementation of final prostheses. **[Table/Fig-22]:** Disocclusion in protrusive movement. (Images from left to right)



[Table/Fig-23]: Disocclusion in left eccentric movement.



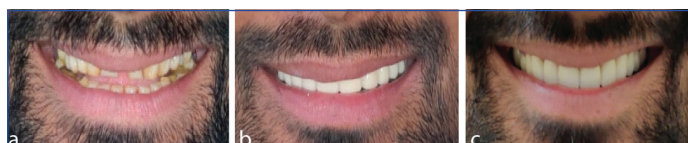
[Table/Fig-24]: Disocclusion in right eccentric movement.



[Table/Fig-25]: Occlusal view.



[Table/Fig-26]: Smile of satisfaction.



[Table/Fig-27]: Smile makeover: (a) pre-operative; (b) provisional restoration; (c) final restoration.

Amelogenesis Imperfecta (AI) is an inherited group of odontological disorders which have the effect of altering the formation of enamel and is often associated with loss of the normal occlusal plane, loss of VDO, compromised functions and aesthetics [1]. The patient, in this case, had a reduced VDO and a 6 mm freeway space, so it was decided to increase the VDO by 3 mm. Full mouth rehabilitation involves the procedures necessary to produce a healthy, aesthetic, well-functioning masticatory system. Healthy Temporomandibular Joint (TMJ), harmonious anterior guidance and non-interfering posteriors are three most important requirements [4]. A diagnostic wax-up is always recommended before treatment to determine appearance, remove occlusal interferences and predict tooth preparation needed [5]. Anterior guidance plays a crucial role in full mouth rehabilitation following centric relation. Anterior guidance serves as an anterior control for posterior disclusion. Anterior guidance protects the back teeth from lateral and protrusive forces [4]. When replacing posterior teeth, achieving posterior disclusion, deciding the plane of occlusion, and choosing the type of occlusal scheme are the three most important factors to be considered [2,6]. The contraindications of Hobo twin stage procedures include abnormal curve of Wilson, curve of Spee, tilted and abnormally rotated teeth [3,7].

Full mouth rehabilitation aims to restore the stomatognathic system's function, aesthetics and biological harmony. A unique feature of Hobo twin stage technique is that it reproduces disocclusion with accuracy and does not require condylar path measurement. Disocclusion can be reproduced precisely as programmed. It ensures optimised occlusion with a predictable posterior disclusion. A relatively simple technique that does not require any special equipment and gives predictable results in minimum appointments.

patient [Table/Fig-27]. The patient was satisfied with the aesthetics and became more confident to engage in social activities.

REFERENCES

- [1] Shafer WG, Hine MK, Levy BM. A textbook of oral pathology. (7th Ed.). Elsevier 2012;3-80.
- [2] Tiwari B, Ladha K, Lalit A, Dwarakananda Naik B. Occlusal concepts in full mouth rehabilitation: An overview. J Indian Prosthodont Soc. 2014;14(4):344-51.
- [3] Hobo S, Takayama H. oral rehabilitation, clinical determination of occlusion. Quintessence Publishing Co. Inc. 1997;32-33.
- [4] Dawson PE. Functional occlusion from TMJ to smile design. (1st Ed.) New York; Elsevier Inc. 2008;430-52.
- [5] Saeidi PR, Engler MLPD, Edelhoff D, Prandtner O, Frei S, Liebermann A. A patient-calibrated individual wax-up as an essential tool for planning and creating a patient-oriented treatment concept for pathological tooth wear. Int J Esthet Dent. 2018;13(4):476-92.
- [6] Chander NG. Deciphering the opinions in full mouth rehabilitation. J Indian Prosthodont Soc. 2020;20(3):225-27.
- [7] Ezzy H, Gaikwad A, Ram S, Shah N, Nadgere J, Iyer J. Full-mouth rehabilitation of worn dentition by hobo twin-stage philosophy: A case series. J Contemp Dent. 2019;9(1):17-24.

PARTICULARS OF CONTRIBUTORS:

1. Medical Officer Dental, Department of Prosthodontics, Rajasthan University of Health Sciences (RUHS) College of Dental Sciences, Jaipur, Rajasthan, India.
2. Professor, Department of Prosthodontics, Rajasthan University of Health Sciences (RUHS) College of Dental Sciences, Jaipur, Rajasthan, India.
3. Senior Demonstrator, Department of Prosthodontics, Rajasthan University of Health Sciences (RUHS) College of Dental Sciences, Jaipur, Rajasthan, India.
4. Senior Demonstrator, Department of Prosthodontics, Rajasthan University of Health Sciences (RUHS) College of Dental Sciences, Jaipur, Rajasthan, India.
5. Private Practitioner, Department of Smile Dental Clinic, Smile Dental Clinic, Palwal, Haryana, India.

NAME, ADDRESS, E-MAIL ID OF THE CORRESPONDING AUTHOR:

Vineet Sharma,
Subhash Nagar, Jaipur, Rajasthan, India.
E-mail: vineetalwar007@gmail.com

PLAGIARISM CHECKING METHODS: [Jain H et al.]

- Plagiarism X-checker: Sep 14, 2021
- Manual Googling: Nov 03, 2021
- iThenticate Software: Nov 19, 2021 (10%)

ETYMOLOGY: Author Origin

AUTHOR DECLARATION:

- Financial or Other Competing Interests: None
- Was informed consent obtained from the subjects involved in the study? Yes
- For any images presented appropriate consent has been obtained from the subjects. Yes

Date of Submission: **Sep 13, 2021**

Date of Peer Review: **Oct 16, 2021**

Date of Acceptance: **Nov 08, 2021**

Date of Publishing: **Dec 01, 2021**